

Sharon Riley, Tissue Viability Nurse, Exeter PCT, Franklyn House, Franklyn Drive, Exmouth, Devon EX2 9HS, email: janine.prytherch@exeter-pct.nhs.uk
Jill Tongue, Tissue Viability Nurse, Exeter PCT, Franklyn House, Franklyn Drive, Exmouth, Devon EX2 9HS, email: jill.tongue@exeter-pct.nhs.uk
Sharon Strokes, Tissue Viability Nurse, Exeter PCT, Franklyn House, Franklyn Drive, Exmouth, Devon EX2 9HS, email: sharon.strokes@exeter-pct.nhs.uk
Lara Jefferies, Clinical Support Nurse, Smith & Nephew Healthcare Ltd, Healthcare House, 101 Hessle Road, Hull HU3 2BN, email: lara.jefferies@smith-nephew.com

Using Negative Pressure Wound Therapy as an aid to debridement

Introduction

Traditionally, Negative Pressure Wound Therapy (NPWT) has been used post debridement as an aid to healing both acute and chronic wounds. Currently, debridement is not thought to be one of the modes of action for NPWT. This case series suggests that NPWT may aid in the debridement of wounds by the removal of body fluids, wound exudates and infectious material during therapy via the removal of body fluids, wound exudates and infectious material, and looks at the potential advantage of this.

Method

In community settings it is not always easy to ensure that the wound bed is completely free of devitalised tissue prior to the application of NPWT. As a result the team decided to monitor patients using NPWT to see how efficient the therapy is in aiding the debridement of wounds. Smith & Nephew's RENASYS[®] GO NPWT device was applied, using the gauze dressing kits with a flat drain. A hydrocolloid was used as a border around the wound to protect the surrounding skin. No wound contact layer was used. NPWT was set at -80mmHg in all cases. When slough/necrosis loosened during therapy it was sharp debrided, if appropriate, in the patient's home.

Results

Patient no.	Wound location	NPWT duration in days	Wound size at commencement of therapy	Wound size on discontinuation	Devitalised tissue on commencement	Devitalised tissue on discontinuation
1	Ischial tuberosity pressure ulcer grade IV*	42	7.5 cm sinus	5cm sinus	Zero	Zero
2	Dehisced abdomen	8	5 x 1.5cm	4 x 1cm	50% slough	Zero
3	Dehisced abdomen	6	3.3 x 1.5 x 3cm	2.5 x 1 x 2cm	40% slough	Lost to follow up
4	Dehisced abdomen	33	5cm and 8cm sinuses	0cm and 4cm	Zero	Zero
5	Dehisced abdomen	8	3 sinuses 2.5cm, 2cm and 3cm 3 sinuses 0cm 0cm and 1cm	0cm/0cm/1cm	Zero	Zero
6	Pressure ulcer buttock	21	2 x 2.5cm +2cm undermining	1 x 1cm undermining healed	80% slough	Zero
7	Pilonidal sinus	10	3 x 2cm	1 x 1cm	Zero	Zero
8	Sacral pressure ulcer	31	2.5 x 1.5cm +2cm undermining	1.5 x 1cm undermining healed	Exposed bone Zero	Bone covered Zero
9	Sacral pressure ulcer	25	3.5 x 2.5+4cm undermining	1.5 x 0.5cm +1cm undermining	60% slough	Zero
10	Sacral pressure ulcer	47	5 x 2cm +2cm undermining	3 x 1cm undermining healed	100% slough	Zero
11	Ischial pressure ulcer	65	7 x 5cm +4cm undermined	2.5 x 2cm undermining healed	100% slough	Zero
12	Lumbar pressure ulcer	34	4cm x 2.5cm	2 x 1.5cm	80% slough	Zero
13	Sacral pressure ulcer	26	4 x 3cm +4cm undermining	2 x 2cm +2cm undermining	75% slough	Zero

*EPUAP grading scale

Discussion

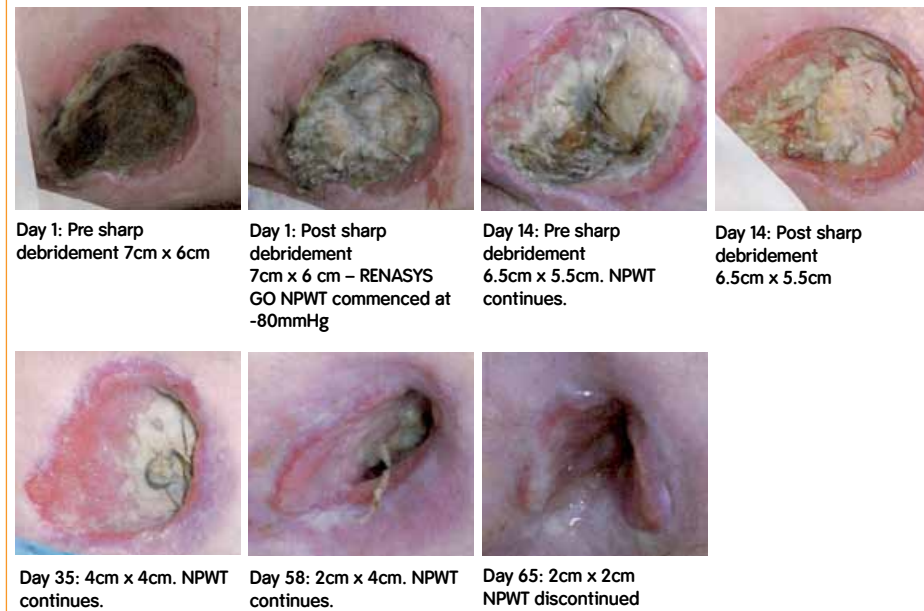
This case series, found that new tissue was stimulated beneath the slough that was present. There have also been suggestions that the open-celled polyurethane foam mechanically debrides the wound bed as the slough is pulled away with the foam as it is removed, however this can be increasingly painful and uncomfortable for the patients¹. In this case series, our findings differ as gauze does not adhere to the wound bed and the slough and necrosis seemed to soften and liquefy during therapy, which aids easier and more effective debridement than some conventional methods. This lack of adhesion was seen as an advantage in the community as it seems to be more acceptable and comfortable for the patient.

Conclusion

The results from this case series would seem to support the use of NPWT as an aid to debridement. Whilst debridement should not be the primary reason for its application nor should it be an absolute contraindication. Further work that compare NPWT vs. conventional dressings in the role of debridement is needed before any definitive conclusions can be drawn with regard to relative benefits.

Case study - Patient 11

A 56-year-old male with Multiple Sclerosis, type 2 diabetic, wheelchair bound, poor eyesight, short term memory loss and faecal incontinence. Presented with a grade IV pressure ulcer on his left Ischial Tuberosity.



The author(s) of this abstract/poster may or may not be employed by Smith & Nephew. These materials are provided for educational use only and do not imply the authors have endorsed Smith & Nephew's products in any way or that the techniques being used are endorsed or recommended by Smith & Nephew.

Reference

- 1 Krasner DL (2002). Managing Wound Pain in Patients with Vacuum-Assisted Closure Devices. *Ostomy Wound Management* 48 (5) Available at: <http://www.o-wm.com/article/461>

This poster was presented at Wounds UK, Harrogate Nov 2009
 This poster was supported by an unrestricted grant from Smith & Nephew.
 *Trademark of Smith & Nephew
 © Smith & Nephew November 2009
 19792